

Commentary on:

Endoscopic Extradural Subtemporal Approach to Lateral and Central Skull Base: A Cadaveric Study

by **Komatsu et al.** pp. 591-597.



Takeshi Kawase, M.D., Ph.D.

Professor and Chairman
Department of Neurosurgery
Keio University School of Medicine

Endoscopic Middle Fossa Approach for Central Skull Base

Takeshi Kawase

The endoscopic approach, one of the minimally invasive surgeries, is combined with skull base techniques to form so-called endoscopic skull base surgery. An important concept of skull base surgery is epidural access to prevent injury to the brain. One of the progressing techniques is endoscopic transsphenoidal surgery; however, the endoscopic middle fossa approach (EMFA) is still undergoing trials. EMFA includes the epidural subtemporal approach to the parasellar area and the petrosal approach to the posterior fossa. Based on the author's long experience with skull base surgery, this commentary suggests the possibilities, pitfalls, and how to spare surgical complications in the clinical application of EMFA.

ENDOSCOPIC EPIDURAL SUBTEMPORAL APPROACH (EESA)

A major complication of the current subtemporal approach has been retraction injury to the temporal lobe, and EESA will be a possible technique to decrease this complication. Resection of epidural or interdural tumors such as parasellar chordomas or trigeminal schwannomas will be a good indication for EESA. The patient is positioned supine with the head elevated and rotated laterally with the axis down. As described in this article, the best keyhole site for the endoscope may be just above the root of the zygoma, where the Drake clip had been used for clipping of basilar tip aneurysms by the subtemporal route in the 1970s. The advantages are a short and straight skin incision and no bridging vein in this area. A burr hole of 2 cm in size must be created flush to the middle skull base to decrease the temporal retraction. A pitfall of this approach that was not clear from the cadaveric study is epidural venous bleeding from the pericavernous venous route, at the elevation of the dura around the foramen ovale and rotundum. Venous variations such as sphenobasal vein (**Figure 1**) or infratemporal vein must be checked before surgery. A further

elevation of the head or plugging the venous route with fibrin glue-dipped Surgicel may reduce the bleeding. Coagulation and detachment of the middle meningeal artery is essential, and may contribute to detaching the feeders. For a dumbbell neurinoma extending into the posterior fossa, an additional petrous apex drilling may be necessary. If the venous bleeding can be controlled, this approach will be a useful surgical method for less vascular parasellar tumors.

ENDOSCOPIC ANTERIOR PETROSAL APPROACH (EAPA)

The anterior petrosal approach is based on the concept of keyhole surgery, and it may be natural to modify this into EAPA in the next step. It can be indicated for trigeminal neurinoma, petrous apex chordoma, cholesterol granuloma, and pontine cavernoma. A burr hole of 2 cm in diameter may be necessary for EAPA to insert the surgical instruments. However, two technical points must be overcome. One is epidural bleeding from the interdural venous route around the foramen ovale. Once it occurs, it will be a shackle for EAPA because insertion of hemostatic materials may obstruct the surgical field. In a case of sphenobasal vein, the venous route around the foramen ovale must be preserved, and pyramidal resection may be made subdurally. The second point is resection of the petrous apex through an endoscopic burr hole. A narrow drill with a long shaft must be used to resect the petrous apex through the burr hole. If pyramidal resection including the posterior half of the trigeminal impression was not completed, mobilization of the trigeminal nerve, which is necessary for further surgical extension, cannot be achieved.

If the endoscope was inserted into the posterior fossa through the resected petrous apex without tentorial incision, one could not obtain enough space for surgical management. By an

Key words

- Cavernous sinus
- Endoscopy
- Infratemporal fossa
- Middle cranial fossa
- Posterior cranial fossa
- Tympanic cavity

Abbreviations and Acronyms

- EAPA:** Endoscopic anterior petrosal approach
- EESA:** Endoscopic epidural subtemporal approach
- EMFA:** Endoscopic middle fossa approach



Department of Neurosurgery, Keio University School of Medicine, Ichikawa, Chiba ken, Japan

To whom correspondence should be addressed: Takeshi Kawase, M.D., Ph.D.
[E mail: kawase@sc.itc.keio.ac.jp]

Citation: *World Neurosurg.* (2013) 80, 5:505-506.
<http://dx.doi.org/10.1016/j.wneu.2013.01.103>

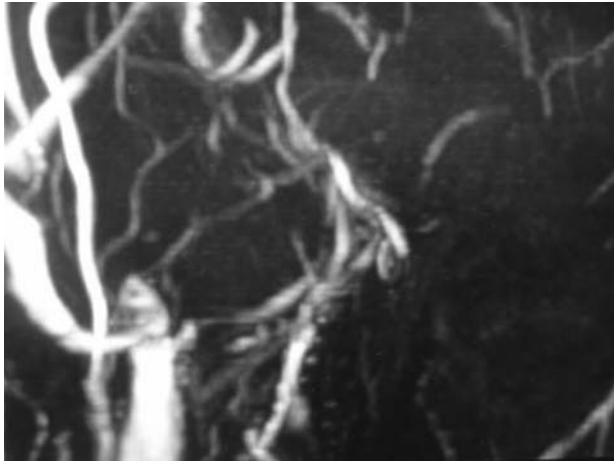


Figure 1. Magnetic resonance venogram in a case of sphenobasal vein, a variation of a drainage pattern of the Sylvian vein, draining into the pterygoid plexus through the foramen ovale, not draining into the cavernous sinus. Severe venous bleeding may occur by the epidural approach.

additional tentorial incision, the surgical field will be enlarged up to 2 cm in diameter, obtaining a surgical field comparable to the microscopic anterior petrosal approach. At the incision of the tentorium, a surgical tool called Maniceps (Mizuho Ika, Tokyo, Japan) will be a convenient tool for ligation of the superior petrosal sinus in a limited space. Sutures for ligation can be used for retraction of the tentorial leaflets. An additional cutting of the lateral dura on the Meckel cave enables mobilization of the trigeminal nerve, which is commonly elongated by compression of the tumor. This mobilization is important to coagulate tumor feeders from the meningohypophyseal trunk, which is commonly located medial to the nerve. Internal tumor decompression is possible after the feeder coagulation using an ultrasonic aspirator. A hooked tumor retractor is definitely necessary for endoscopic work to remove the marginal tumor in a blind corner. By combined use of a curved tumor dissector and retractor, the dissection plane in a blind corner will come up

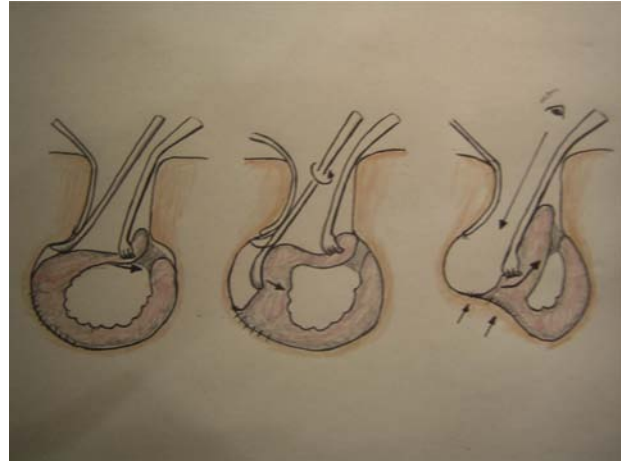


Figure 2. A keyhole technique to dissect the tumor margin in the blind corner. After internal tumor decompression, the margin is retracted away from the brainstem and a curved dissector is inserted along the dissection layer (*left*). By rotation of the dissector, the tumor margin is on view (*center*). The tumor retractor is replaced to find a new dissection plane (*right*). The tumor retraction is made away from the brainstem (*arrows*), and no there is retraction damage to neurovascular structures.

in the keyhole (**Figure 2**). With this technique, a larger and non-suckable tumor will be able to be removed from a narrow surgical field. Neurovascular structures, the abducens nerve, the anterior inferior cerebellar artery, and the basilar trunk in the prepontine cistern will be feasible by retraction of the marginal tumor. Indication of EAPA for petroclival meningioma is justifiable for the surgeon who has mastered this technique.

Citation: *World Neurosurg.* (2013) 80, 5:505-506.
<http://dx.doi.org/10.1016/j.wneu.2013.01.103>

Journal homepage: www.WORLDNEUROSURGERY.org

Available online: www.sciencedirect.com

1878 8750/\$ see front matter © 2013 Elsevier Inc. All rights reserved.